

EEG Abnormalities in Children with Speech and Language Impairment

BHARATI MEHTA¹, V. K. CHAWLA², MANISH PARAKH³, POONAM PARAKH⁴, BHARTI BHANDARI⁵, ANOOP SINGH GURJAR⁶

ABSTRACT

Introduction: Epilepsy, a chronic condition of recurrent seizures, affects language, but the extent and nature of the language disturbance varies widely according to the type, severity, and cause of the epilepsy. There is paucity of literature on the electroencephalographic abnormalities in children with speech and language impairment. The present study was therefore planned to find the association of epileptiform EEG abnormalities in children with speech and language impairment and if present, their localization and lateralization to the language areas of the brain that are present predominantly in the left hemisphere.

Materials and Methods: The study was conducted on Paediatric patients having speech and language impairment (n=94, age-2 to 8 years) selected on the basis of detailed history and neurologic examination. Video Electroencephalography (EEG) was performed as per American Clinical Neurophysiology Society guidelines using 16 channel RMS computerized EEG machine for a minimum of 40 minutes to capture both wakefulness and sleep along with activation procedures like hyperventilation (if feasible) and photic stimulation. EEG was

reviewed for any abnormal EEG background, benign variants, interictal epileptiform discharges and ictal discharges.

Results: In our cohort, 19.7% boys and 22.2% girls presented with seizures in their infancy and this gender difference was found to be statistically significant ($p < 0.05$). EEG was abnormal in 47.9% children (45 out of 94) with no significant gender difference. Epileptiform EEG was seen in 73.6% of children with history of seizures and 41.3% of children without history of seizures ($p < 0.05$). The EEG abnormalities included: abnormal background (64.5%), presence of generalized interictal epileptiform discharges (57.8%), focal epileptiform discharges (20%) exclusively from left hemisphere and multifocal interictal epileptiform discharges (33.3%), each occurring in isolation or associated with other abnormalities.

Conclusion: In the current study, it is definite that presence of generalized abnormalities in EEG are seen in higher frequency and focal interictal epileptiform discharges are solely seen in left hemisphere in children with speech and language impairment. Although, there is no distinct pattern of EEG abnormalities in such patients, we recommend a routine EEG in them and also brain imaging to complement the EEG findings.

Keywords: Epilepsy, Electroencephalography, Language and speech disorders

INTRODUCTION

Developmental language and speech disorders constitute a large Group of paediatric patients with neurologic morbidity and pose significant burden on the health care system. The prevalence of speech delay among six-year-old children is about 4% with high male to female ratio [1]. Speech and language impairment is also a common concurrence with a number of neuro-developmental abnormalities. Language ability is an excellent example of early cortical plasticity coupled with later permanence. In majority of people, the primary brain areas concerned with speech and language are located in the left hemisphere [2]. Researchers have always been interested by the variety of ways in which language can be afflicted by neurological disorders. Epilepsy may co-occur with speech and language disorders, and it may be the cause of differences in language development [3]. A few studies in the past have shown that speech and language impairment is more common in patients with partial epilepsy arising in the left hemisphere. A few epilepsies including benign childhood epilepsy with centrotemporal spikes (BECTS), Landau Kleffner syndrome, Electrical status epileptics in sleep (ESES) & Lennox Gestaut Syndrome have a higher association with speech and language abnormalities [3]. Developmentally dysphasic children exhibit a higher incidence of abnormal EEG than expected [4]. It is however not clear whether epilepsy contributes to the pathogenesis of speech and language impairment or whether it is merely an association with speech and language impairment in a wider syndromic diagnosis. It is also not clear whether the epileptiform discharges or other EEG abnormalities

localize to areas of brain that are involved in the functional control of speech and language. The present study was therefore conceived and planned to examine the different forms of epileptiform EEG abnormalities, their localization and lateralization in children with speech and language impairment.

MATERIALS AND METHODS

The current study was a observational cross-sectional study conducted in the Department of Physiology, in association with Paediatric Neurology Clinic in Department of Paediatrics. Of the 1641 patients that attended neurology clinic from 2011 to 2014, children between age group 2-8 years presenting predominantly with speech and language impairment were selected for our study. Those with age less than 24 months and more than 8 years, having any gross motor developmental delay, head injury, frank hearing impairment, cleft lip/palate and autism were excluded from the study [5]. Ninety four patients having speech and language impairment were finally enrolled, out of which 18 were girls and 76 boys. Sample size was calculated by using nMaster 1.0 software (KMC, Vellore). After obtaining the permission from institutional ethical committee, informed consent from parents of children was obtained for the study. A detailed history of the patients was obtained from the parents which included prenatal, perinatal, postnatal history, family history for any speech and language disorders & seizures and neurodevelopmental history. Detailed neurologic examination was performed by a Paediatric neurologist and results of any previous neuroimaging were documented in a predesigned proforma.

In all these patients, standard video EEG was performed for a minimum of 40 minutes to capture both wakefulness and sleep in stage II NREM. A 16 channel RMS computerized EEG machine with a synchronized video EEG recording was used for this purpose and activation procedures included hyperventilation (if feasible) and photic stimulation. The montages used were those of 10:20 international system of recording and as per ACNS (American Clinical Neurophysiology Society) guidelines, both bipolar and referential montages were used. The EEG recordings were reviewed by a trained paediatric neurologist and electrophysiologist to identify age appropriate EEG background, benign variants, abnormalities including interictal epileptiform discharges and ictal discharges (if any). Focal or diffused hyperactive epileptic activity, its localization and temporal characteristics were specifically elaborated. Epileptiform waves or activity, according to the International Federation of Societies for Electroencephalography and clinical Neurophysiology (IFSECN) have been defined as "distinctive waves or complexes, distinguished from background activity, and resembling those recorded in a proportion of human subjects suffering from epileptic disorders" [6].

RESULTS

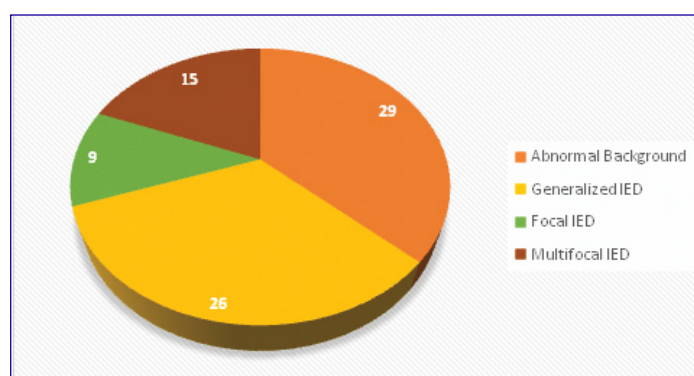
A total of 1641 patients attended neurology clinic between 2011 and 2014. After using the exclusion criteria the final cohort constituted 94 (5.68 %) children in the age group of 2 to 8 years, out of which 18 (19.14 %) were females and 76 (80.86%) were males. The mean age of whole cohort was 50.3 ± 19.7 months and was 49.3 ± 19.5 months in female children and 51.3 ± 20.0 months in male children. Fifteen (16%) children had family history of seizures (12, 12.78 % were boys and 3, 3.19 % were girls). In our cohort, 19 children (15 boys and 4 girls) had history of seizures during their first year of life. Fifteen out of 76 boys (19.7%) and 4 out of 18 girls (22.2%) presented with seizures in their infancy and this gender difference was found to be statistically significant ($\chi^2=4.22$, $df=1$ p-value=0.04). Gender wise distribution of the cohort with seizures is shown in [Table/Fig-1].

EEG	History of Seizures		No history of seizures		Total
	Males	Females	Males	Females	
Normal	05(10.2)	00(00)	35(71.4)	09(18.3)	49(100)
Abnormal	10(22.2)	04(8.8)	26(57.7)	05(11.1)	45(100)
Total	15(15.9)	04(4.2)	61(64.9)	14(14.9)	94(100)

[Table/Fig-1]: Gender wise distribution of children having history of seizures with epileptiform EEG. Figures in parentheses indicate percentage

Abnormalities	Present	Absent	Total
Abnormal Background	29(64.5)	16(35.5)	45
Generalized IED	26(57.8)	19(42.8)	45
Focal IED	09(20.0)	36(80.0)	45
Multifocal IED	15(33.3)	30(66.7)	45

[Table/Fig-2]: EEG abnormalities in children with speech and language impairment (N=45). Figures in parenthesis indicate percentage



[Table/Fig-3]: Forms of EEG Abnormalities seen in children

EEG was performed in all children with developmental speech and language impairment and was abnormal in 47.9% (n= 45; 36 boys and 9 girls) children and normal in 52.1% (n=49; 40 boys and 9 girls) children. This difference in abnormal EEG of male versus females (47.4% boys and 50% girls) was not statistically significant ($\chi^2=0.04$, $df=1$, p-value=0.84). Epileptiform EEG was seen in 14(73.6%) out of the 19 children with history of seizures and in 31(41.3%) out of 75 children without history of seizures and this difference was statistically significant ($\chi^2=6.35$, $df=1$, p-value=0.01). In the abnormal EEG found in 45 (47.9%) out of 94 patients, 64.5% (n=29) children had an abnormal background, 57.8% (n=26) had presence of generalized interictal epileptiform discharges, 20% (n=9) had focal epileptiform discharges and 33.3% (n=15) had multifocal interictal epileptiform discharges occurring both in isolation and also associated with other abnormalities [Table/Fig-2,3]. The major abnormalities included presence of sharp waves, spikes/polyspikes and spike-wave complexes and slow activities (Frontal intermittent rhythmic discharges and occipital intermittent rhythmic discharges). Abnormal background on EEG was mostly seen as presence of a slow and high amplitude sleep background with absence or paucity of normal age appropriate physiologic features of stage II NREM sleep. EEG of 15 children (33.3%) showed multifocal interictal epileptiform discharges along with associated generalized discharges in 7 (15.5%) patients. Focal inter-ictal discharges in the form of sharp waves and spikes originating from left hemisphere were seen in 9 (20%) children having abnormal EEG and localized to the fronto-central region in 4 (4.2%) children, followed by centro-parietal in 3 (3.1%), temporal lobe alone in 1(1.0%) child and frontal lobe alone in 1(1.0%) child.

DISCUSSION

Specific language impairment (SLI) is a primary developmental disorder in which language is significantly more impaired than other developmental domains affecting 15-20% of Indian population with a male predominance [7]. A study in the west observed the prevalence of speech delay among six-year-old children to be about 4% with high male to female ratio [1].

Many authors in the past have tried to evaluate EEG changes seen in children with speech and language impairment and demonstrated that it can be used for prognosis of these patients [8]. In one of our studies, we have observed that developmental speech and language impairment is not associated with any abnormalities in Auditory Brainstem Evoked Responses [9]. The bigger question is whether some specific EEG abnormalities are present in children with speech and language impairment/delay? If present do they localize to a specific language area? The current study was conceived to find out an answer to the aforementioned questions. In the current study, an abnormal EEG was seen in 47.9% (n= 45) children with developmental speech and language impairment and was normal in 52.1% (n=49) children. This observation definitely makes a persuasive case that speech and language impairment is related to abnormal EEG findings and is further supported by the fact that 64.3% children with speech and language impairment having seizures have an abnormal interictal EEG (mostly presence of epileptiform discharges) and almost 41.4% children with speech and language impairment without history of clinical seizures also have an abnormal EEG. Our study also revealed presence of varying EEG abnormalities in SLD including abnormal background (64.5%), generalized interictal epileptiform discharges (57.8%), multifocal interictal epileptiform discharges (33.3%), and focal epileptiform discharges (20%) occurring both in isolation or in combination with other abnormalities. Moreover, in about 15.5% children, multifocal discharges were associated with generalized interictal epileptiform discharges. Based on the aforementioned observations, it seems that developmental speech and language impairment in children may be the result of a global dysfunction of brain physiology. More research is however required to provide inputs into how specifically

the speech and language function is affected due to the presence of these generalized/multifocal brain electro physiologic changes. Previous studies have consistently shown seizure to be a major complication among children with developmental speech disorders. Consequently, and coupled with a possible association between abnormal EEG and developmental regression, some clinicians advocate an EEG recording as a routine [10]. Some studies have also demonstrated that abnormal electroencephalographic recordings without clinical seizures can be observed [11]. Billard et al., performed a cohort study on 24 children with diagnosed SLI with the aim to study the relations between epileptiform activity (EA) and language disorders. He concluded that there is no parallel between EEG progression and language development, contrary to Landau-Kleffner's syndrome [12]. Developmentally aphasic children show a higher incidence of abnormal EEG than expected, particularly during overall night recording [4]. A study attributes subtle brain damage as a possible cause of seizure and/or high percentage of EEG abnormalities found in developmental speech disorders [13]. The finding of epileptiform activity being the commonest EEG abnormality seen in SLI patients with or without history of clinical seizures is in agreement with previous findings in prolonged EEG recordings on such subjects [14]. Interactions between language and epilepsy may range from mild EEG abnormalities during sleep to benign conditions as BECTS (benign childhood epilepsy with centrotemporal spikes) and finally the debilitating acquired aphasia in Landau-Kleffner syndrome (LKS) [12].

In our study, focal inter-ictal discharges in the form of sharp waves and spikes originating from left hemisphere were seen in almost 20% children having abnormal EEG and were localized to the fronto-central region in 4 (4.2%) children, followed by centro-parietal in 3 (3.1%), temporal lobe alone in 1 (1.0%) child and frontal lobe alone in 1 (1.0%) child. The present study also investigated whether the left hemisphere was the dominant hemisphere in all these children who had left sided focal interictal epileptiform discharges. However, most of these children had yet developed handedness and it was difficult to comment on the fact whether the left hemisphere was dominant hemisphere and controlled speech and language in these children. Levy et al., did a retrospective study on 35 children of age group 4-7 years with the aim to characterize the frequency of abnormal electroencephalographic recordings without clinical seizures. In this population, 49% (n = 17) of patients exhibited a specific expressive language disorder and 51% (n = 18) a specific receptive disorder. Forty-nine percent of the children featured abnormal electroencephalography results [11]. In this study also, abnormalities were essentially localized on the left side of the brain and supports observations made in our study. These abnormalities were more frequent in children with a severe phonological disorder, suggesting that they may share common pathophysiological features with SLI. Focal epileptic discharges, even if not culminating to clinical seizures, may cause transient cognitive deficit in some cases [15]. Also, several cases of transient oromotor, speech, language, or cognitive dysfunction occurring during active stage of the BPERS (benign partial epilepsy of childhood with rolandic spikes) have been reported suggesting a strong connection between cognitive function and epilepsy [16]. In our cohort, focal inter-ictal discharges were seen in nine patients and found over the fronto-temporal region, followed by temporal lobe and frontal lobe and in all of them, the discharges were in form of sharp waves and spikes arising exclusively from left hemisphere. With respect to the localization of focal epileptiform activity, these abnormalities are in accordance with those from previous studies where the left temporal and frontal lobes or fronto/temporal regions were the commonest sites for focal EEG abnormalities [13,17]. A study reported the likelihood of focal paroxysmal abnormalities and language impairment to be related to architectural dysplasia and neuron-migration disturbances and postulated these focal paroxysmal abnormalities as a causative factor for speech and language deterioration [18]. It is therefore

concluded that left hemisphere somehow has the dominant role in speech and language impairment and more studies are suggested in future to evaluate this observation. It may be possible that even when generalized EEG abnormalities are present in children with speech and language impairment, left hemispheric abnormalities as a part of this generalized dysfunction may be responsible for the speech and language dysfunction. Interictal epileptiform discharges can interfere with the development of contralateral hemispheric function in the absence of clinical seizures [2]. It will therefore be very interesting to look into specific left hemispheric structural and aetio-pathologic correlates of speech and language impairment.

However, why did almost 35.7% children with history of clinical seizures and speech and language impairment in the current study had a normal interictal EEG is very difficult to explain. It also remains unclear as to what is the mechanism of speech and language impairment in 58.6% children without history of clinical seizures and having a normal EEG in the current study.

CONCLUSION

In the current study, we found a spectrum of epileptiform EEG abnormalities ranging from attenuation of background sleep features to generalized, multifocal and focal interictal discharges. It is definite that presence of generalized abnormalities in EEG are seen in higher frequency with speech and language impairment and focal interictal epileptiform discharges are solely seen in left hemisphere in these children. The localization as well as lateralization of such abnormalities was in agreement with previous studies. Although, there is no specific pattern of EEG abnormalities associated with speech and language delay/impairment and even though information on the potential efficacy of antiepileptic treatment to improve language in children with an epileptiform EEG is still lacking, we recommend a routine EEG in all these children. In addition, brain imaging could be done to complement the EEG findings. Further, research to unravel the electro-physiologic basis of speech and language impairment is recommended in future to provide insight into targeted and specific pharmacologic and non-pharmacologic treatment of speech and language impairment.

REFERENCES

- [1] Shriberg LD, Tomblin JB, McSweeney JL. Prevalence of speech delay in 6-year-old children and comorbidity with language impairment. *J Speech Lang Hear Res.* 1999;42:1461-81.
- [2] Rosenblatt B, Vernet O, Montes JL, Andermann F, Schwartz S, Taylor LB, et al. Continuous Unilateral Epileptiform Discharge and Language Delay: Effect of Functional Hemispherectomy on Language Acquisition. *Epilepsia.* 1998;39:787-92.
- [3] Ballaban-Gil K, Tuchman R. Epilepsy and epileptiform EEG: association with autism and language disorders. *Ment Retard Dev Disabil Res Rev.* 2000;6:300-08.
- [4] Echenne B, Cherminal R, Rivier F, Negre C, Touchon J, Billiard M. Epileptic electroencephalographic abnormalities and developmental dysphasias: a study of 32 patients. *Brain Dev.* 1992;14:216-25.
- [5] Alexander KC, Leung CPK. Evaluation and Management of the Child with Speech Delay. *Am Fam Physician.* 1999;59:3121-28.
- [6] IFSECN. International Federation of Societies for Electroencephalography and Clinical Neurophysiology. A glossary of terms most commonly used by clinical Electroencephalographers. *Electroencephalography and Clinical Neurophysiology.* 1974;37:538-48.
- [7] Parakh M, Parakh P, Bhansali S, Gurjar AS, Parakh P, Mathur G. A clinico-epidemiologic study of neurologic associations and factors related to speech and language delay. *Natl J Community Med.* 2012;3:518-22.
- [8] Panayiotopoulos CP, Michael M, Sanders S, Valeta T, Koutroumanidis M. Benign childhood focal epilepsies: assessment of established and newly recognized syndromes. *Brain J Neurol.* 2008;131:2264-86.
- [9] Mehta B, Chawla VK, Parakh M, Bhandari B, Gurjar AS. ABER assessment in pre-school children with developmental speech and language impairment. *Journal of Clinical and Diagnostic Research.* 2015;9(5):CC01-CC03.
- [10] Wing L. The autistic spectrum. *Lancet.* 1997;350(9093):1761-66.
- [11] Lévy-Rueff M, Bourgeois M, Assous A, Beauquier-Maccota B, Boucheron E, Clouard C, et al. Abnormal electroencephalography results and specific language impairment: towards a theoretical neurodevelopmental model? *L'Encéphale.* 2012;38(4):318-28.
- [12] Billard C, Fluss J, Pinton F. Specific language impairment versus Landau-Kleffner syndrome. *Epilepsia.* 2009;50:21-24.
- [13] Aina OF, Ogun OC, Ladapo HT, Lesi FE, Famuyiwa OO. Clinical neuropsychiatric correlates and EEG findings among children with developmental disorders in Lagos, Nigeria. *Afr J Psychiatry.* 2008;11:123-27.

- [14] Tuchman RF, Rapin I. Regression in pervasive developmental disorders: seizures and epileptiform electroencephalogram correlates. *Paediatrics*. 1997;99:560–66.
- [15] Binnie CD, de Silva M, Hurst A. Rolandic spikes and cognitive function. *Epilepsy Res Suppl*. 1992;6:71–73.
- [16] Deonna T, Zesiger P, Davidoff V, Maeder M, Mayor C, Roulet E. Benign partial epilepsy of childhood: a longitudinal neuropsychological and EEG study of cognitive function. *Dev Med Child Neurol*. 2000;42:595–603.
- [17] Shewmon DA, Erwin RJ. Focal spike-induced cerebral dysfunction is related to the after-coming slow wave. *Ann Neurol*. 1988;23:131–37.
- [18] Picard A, Cheliout Heraut F, Bouskraoui M, Lemoine M, Laceret P, Delattre J. Sleep EEG and developmental dysphasia. *Dev Med Child Neurol*. 1998;40:595–99.

PARTICULARS OF CONTRIBUTORS:

1. Associate Professor, Department of Physiology, All India Institute of Medical Sciences, Jodhpur, India.
2. Professor and Head, Department of Physiology, Jodhpur Medical College & Hospitals, Boranada, Jodhpur, India.
3. Professor, Department of Paediatrics, Dr SN Medical College, Jodhpur, India.
4. Assistant Professor, Department of Obstetrics and Gynaecology, Dr SN Medical College, Jodhpur, India.
5. Assistant Professor, Department of Physiology, AIIMS, Jodhpur, India.
6. Assistant Professor, Department of Anatomy, Dr SNMC, Jodhpur, India.

NAME, ADDRESS, E-MAIL ID OF THE CORRESPONDING AUTHOR:

Dr. Bharati Mehta,
Associate Professor, Department of Physiology, AIIMS, Jodhpur, Rajasthan-342005, India.
E-mail : drbharati2005@yahoo.com

Date of Submission: **Mar 09, 2015**

Date of Peer Review: **Mar 23, 2015**

Date of Acceptance: **May 13, 2015**

Date of Publishing: **Jul 01, 2015**

FINANCIAL OR OTHER COMPETING INTERESTS: None.